Fat Grafting to the Breast: Clinical Applications and Outcomes for Reconstructive Surgery

Evan B. Katzel, MD
Louis P. Bucky, MD
Philadelphia, Pa.

Summary: This article is a review of fat grafting for breast reconstruction. The use of small volume fat grafting for the correction of step-off deformities, intrinsic deformities, and extrinsic deformities of the breast, and the uses of large volume fat grafting for total breast reconstruction, correction of implant complications with simultaneous implant exchange with fat, and correction of noncancer chest wall deformities is reviewed. Cancer monitoring and the risks of cancer recurrence following fat-grafting to the breast is also reviewed. (*Plast. Reconstr. Surg.* 140: 69S, 2017.)

Fat grafting for the correction of facial deformities was first introduced in the German literature in 1893.[1] In 1895, Czerny reported the first case of fat grafting to the breast when he utilized an excised lipoma for breast reconstruction.[2] Ninety years later, liposuction was introduced by Illouz,[3] thus allowing plastic surgeons to utilize harvested fat for grafting in both augmentation and reconstruction.[4–7] This revival was short lived, however, when the American Society of Plastic and Reconstructive Surgeons condemned autologous fat grafting to the breast due to perceived impairment in cancer detection and a concern for increased cancer risk.[8] Fat grafting for facial rejuvenation, however, continued to advance and[9–11] fat transfer to the breast remained a popular area of research in Europe.[12–14]

In 2007, Coleman and Saboeiro[15] published long-term follow-up of 17 fat grafting procedures to the breast with good cosmetic outcomes and normal postoperative mammogram findings. These works led the American Society of Plastic Surgeons to change its official position, stating that fat grafting may be considered for augmentation and acquired defects from prior breast surgery,[16] opening the door for today's current clinical renaissance in fat grafting to the breast.

Today, fat grafting for breast reconstruction can be divided into small volume and large volume procedures. Small volume fat grafting is no longer controversial and has become common practice for step-off deformities and contour irregularities.[17,18] More recent work has also elucidated the viability and safety of large volume fat grafting for breast reconstruction. This article discusses the clinical applications as well as safety and efficacy of both small and large volume fat grafting for breast reconstruction.

From The Division of Plastic Surgery, University of Pennsylvania; and the Pennsylvania Hospital.
Received for publication June 15, 2017; accepted August 17, 2017.

DOI: 10.1097/PRS.0000000000003945

SMALL VOLUME FAT GRAFTING

While flap and implant-based reconstructions remain the primary methods of breast reconstruction, autologous fat grafting has become a common tool for the correction of contour irregularities.[13,17,19–22] We believe that graft take is largely dictated by interstitial pressures, thus small volume reconstruction does not require elaborate processing techniques. Based on the volume of fat required, we prefer to harvest the fat for small volume fat grafting with 10 cc syringes and process this fat by rolling on telfa. In order to better understand and correct contour irregularities with small volume fat grafting (less than 100 cc), Kanchwala et al.[18] classified these deformities into 3 groups: step-off deformities, intrinsic defects, and extrinsic defects.

Step-Off Deformities

Step-off deformities are defined as irregular contours created by the transition from the reconstructed breast to the native chest wall. These deformities are generally caused by an over-aggressive superior chest mastectomy excision, an inadequate amount reconstructive tissue in the upper pole, or a combination of both. The medial border of the

Disclosure: *Dr. Bucky is a partner in Peninsula Partners Medical consulting group. He has no direct conflicts. Dr. Katzel has no disclosures.*

reconstructed breast is also frequently affected by this type of deformity. Correction of deformities in these areas are often paramount to the creation of an ideal reconstruction because they are visible in low-cut clothing and bathing suits.

In implant-based breast reconstruction, we prefer to preemptively address step-off deformities at the time of permanent implant placement. Lipoaugmentation is performed in the upper pole of the breast at the interface of the implant and the chest wall, as well as in the medial cleavage plane (Fig. 1). Limiting capsulotomies in these areas is critical to this technique to ensure that the transplanted fat remains outside of the implant pocket in a well-vascularized plane.

Intrinsic Defects

Intrinsic defects are caused by fat necrosis in flap reconstructions or rippling following implant-based reconstruction. We address intrinsic defects caused by implant rippling by fat grafting in the subcutaneous plane between the skin and implant capsule. Blunt tip cannulas 19 gauge or large are utilized to ensure neither the capsule nor the implant are violated (Fig. 2).

Extrinsic Defects

Extrinsic defects caused by radiation, extensive scarring, and postlumpectomy defects well to lipofilling. We utilize needle band release and lipofilling for these defects (Fig. 2). However, more conservative lipofilling for these defects is prudent because scarred or radiated tissue is less compliant leading to increased risk of fat necrosis or cyst formation.[21] Thus, reconstruction of radiation defects need to be carefully performed to avoid necrosis and confusion with new breast lumps or calcifications.

MEGAVOLUME FAT GRAFTING IN RECONSTRUCTION

While small volume fat grafting was a natural extension from what we learned from facial fat grafting, the process associated with small volume fat grafting was not complex. The introduction of large volume (100—300 cc) and megavolume fat grafting to the breast (defined as greater than 300 cc/breast) requires careful thought regarding the entire process. Specifically, the harvesting, purification, and placement of the fat, along with recipient-site modification are all critical in providing successful outcomes for the patients' breasts and entire well-being. In general, utilizing mutli-hole cannula harvests with similar sized infiltrating cannulas is highly suggested in order to avoid blockage and accidental bolus infiltration. Second, while there are many methods of purification and processing, the idea of gentle dehydration

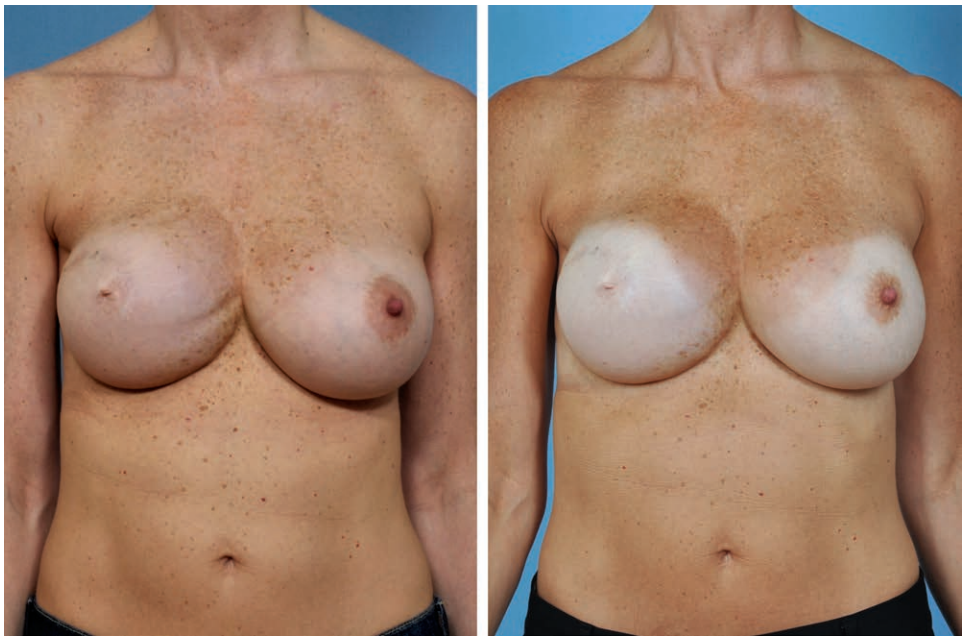

Fig. 1. A postmastectomy breast reconstruction patient with intrinsic and extrinsic defects following right total mastectomy and implant-based reconstruction (*left*). The defects breast corrected with 30 cc of autologous fat grafting. Nine months postoperatively, the patient has good correction of these deformities (*right*).

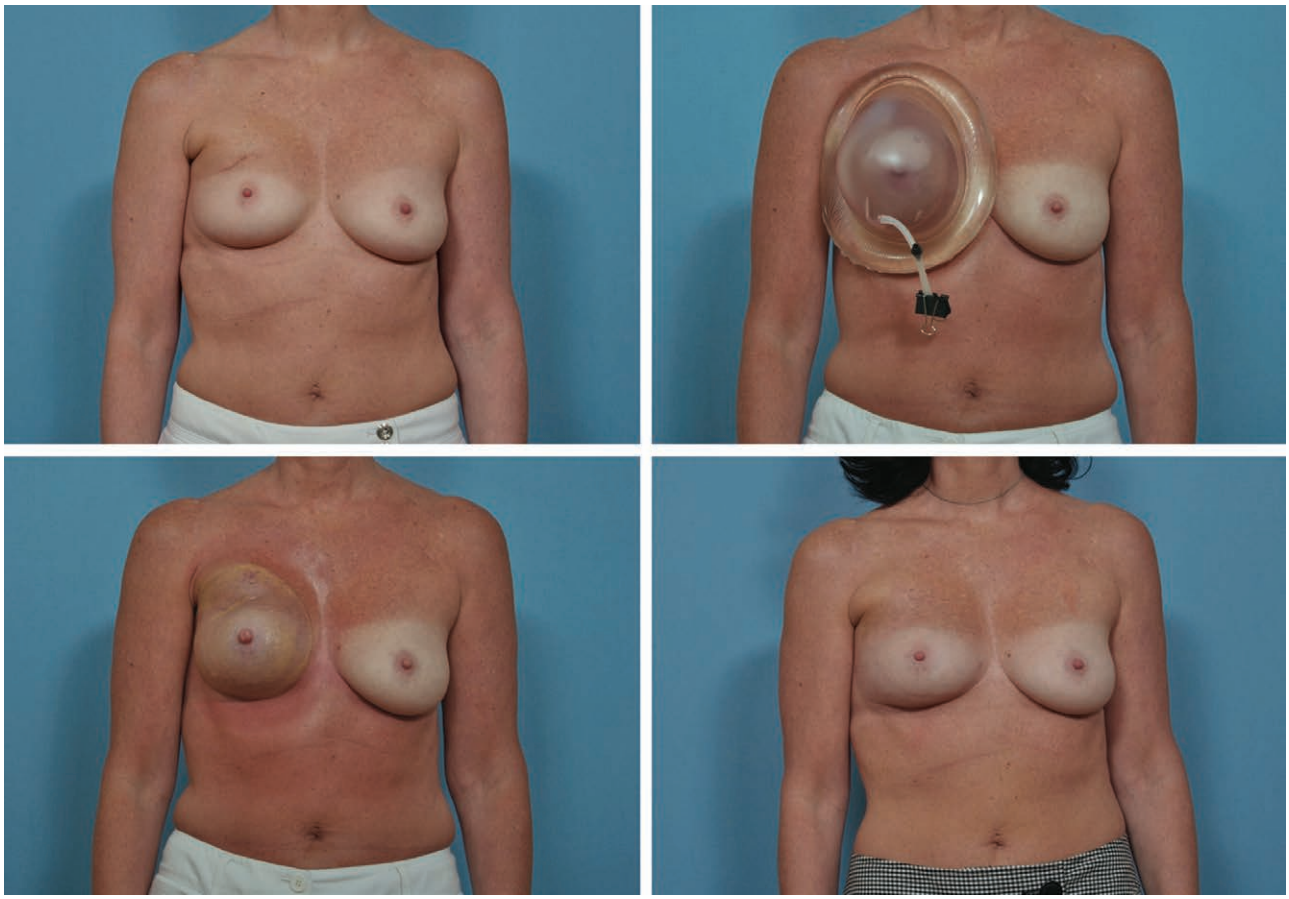

Fig. 2. A right breast lumpectomy defect following whole breast irradiation (*upper, left*). This was treated with BRAVA (*upper, right*), aggressive needle band release, and 525 cc of autologous fat (*lower, left*). At 6 months follow-up, she has good correction of this defect (*lower, right*).

and tissue preservation should be obtained while maximizing efficiency in order to avoid lengthy operative times and subsequent increased morbidity. For large and megavolume fat grafting, we prefer to harvest fat with standard suction-assisted liposuction, and purify the fat in 60 cc syringes in a hand-cranked centrifuge. In reconstructive surgery, we often face tight skin envelopes with inadequate soft-tissue lining; therefore, preexpansion can facilitate larger fat graft volumes while identifying cicatricial adhesions that require needle band release. The most important variable in large volume fat grafting is the judgment and planning associated with infiltration. The idea by Del Vecchio and Del Vecchio[23] of graft to capacity ratio ensuring adequacy of the recipient site and avoiding over filling is the key concept to successful large volume fat grafting. The importance of not over grafting and avoiding fat necrosis, cyst formation, and volume loss are critical in this highly sensitive patient population.

In 2000, Khouri et al.[24] introduced the BRAVA system for nonsurgical breast enlargement. While the system was originally introduced for nonsurgical breast enhancement, it opened the door for mega-volume grafting to the breast in both cosmetic and reconstructive cases.[25–27] While BRAVA claimed to increase capacity, upregulate growth factors, and increase the recipient-site vascularity,[28] it is clear that the most important value of BRAVA in megavolume fat grafting is the ability to increase the graft to capacity ratio, therefore allowing more fat to be safely infiltrated into the preexpanded recipient site. Ancillary techniques such as lipotumescence with subsequent needle band release of adhesions and restrictions were facilitated by BRAVA and megavolume fat grafting.

Determining the adequacy of infiltration and avoiding the deleterious effects of over infiltration are critical to successful megavolume fat grafting. Qualitative assessments such as assessing the surrounding skin for peau d'orange, firmness of the surrounding breast, and resistance to further infiltration were complimented by quantitative assessments such as monitoring interstitial pressure and 3D preoperative planning. Megavolume fat

grafting without BRAVA can also be successful, but with smaller volumes of infiltration over more sessions due to reduced graft to capacity ratio. Lastly, it is important to keep in mind that fat is soft and has no expansile capabilities and thus should only be used as a passive soft-tissue filler.

Total Reconstruction

Total reconstruction is still not a commonplace procedure. The majority of megavolume reconstruction is still performed in combination with implants or flaps. Total breast reconstruction using total autologous fat is still uncommon but has been reported by Khouri et al.[29] In their experience, 87 procedures were performed for immediate total breast reconstruction and 430 were for delayed total breast reconstruction. Complete reconstruction required 2.8 procedures on average for nonirradiated breasts and 4.2 for irradiated tissues. The mean volume grafted per procedure was 225 cc per breast. Other smaller cohorts have shared similar promising results for total breast reconstruction using the BRAVA system.[30]

The major concern with mega-volume fat grafting has been fat necrosis; Chang et al.[31] studied risk factors contributing to fat necrosis following 170 autologous fat grafting procedures with a mean grafted volume of 336.9 cc. They found an overall fat necrosis rate of 32.9%, with a higher rate (47.8%) in irradiated breasts and a lower rate (30.6%) in nonirradiated tissue. They also found that necrosis was significantly more likely in grafts larger than 500 cc in volume.

Augmentation to Implant Reconstruction

Composite breast reconstruction utilizing tissue expanders and implants, in combination with large or mega-volume fat grafting, is becoming a more common treatment plan for mastectomy reconstruction. We perform this technique by first placing tissue expanders in the standard submuscular fashion. At the time of permanent implant placement, we then perform large or mega-volume fat grafting using hand-cranked centrifuged fat in 60 cc syringes to augment the upper pole of the breast, camouflage the upper edge of the implant, and narrow the cleavage plane (Fig. 3). In addition, direct-to-implant reconstruction with subsequent fat grafting is becoming increasingly more popular. Fat can be used to add thickness to thin mastectomy flaps by grafting in the subcutaneous plane within the dermis. Subsequently, fat can be utilized between the dermis and the implant capsule or dermis and acellular dermal matrix if utilized.

Augmentation to Flaps

Mega-volume and large volume fat grafting can also be beneficial for augmenting flap-based breast reconstruction. In these patients, fat grafting can be used in a similar fashion as in implant reconstruction to camouflage the transition between the flap and the native chest wall. Additionally, fat grafting can be used to augment the overall volume of smaller flaps or failed flaps (Fig. 4). Some authors opt to fat graft potential flaps prior to free flap transfer[32]; however, more commonly, fat grafting is performed following flap reconstruction. Other groups have opted to

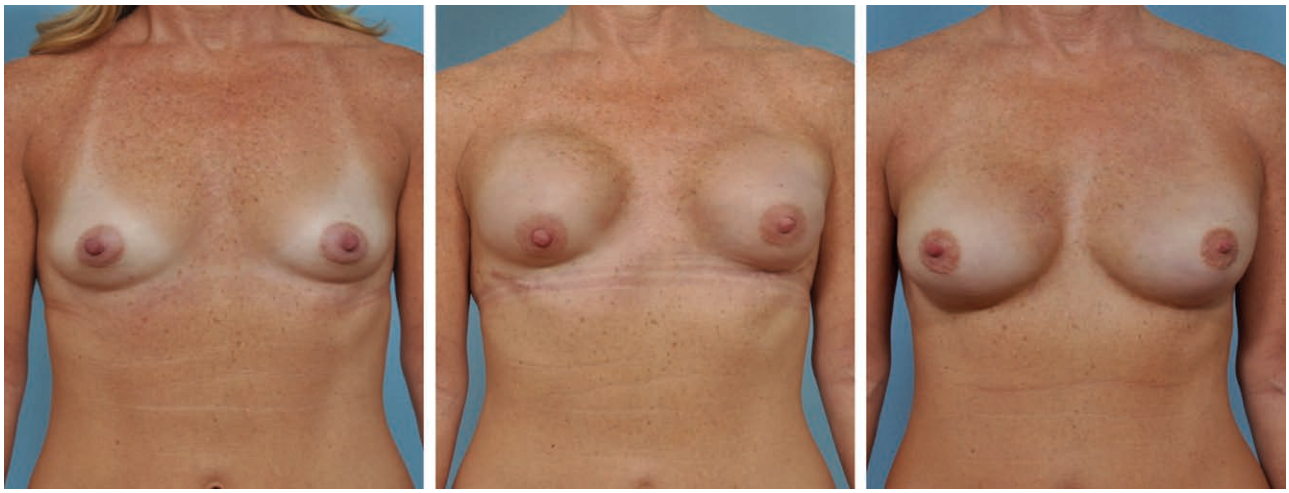

Fig. 3. A breast reconstruction patient is pictured, prior to bilateral nipple-sparing mastectomy (*left*) and following full expansion of bilateral tissue expanders with full muscle coverage (*center*). At 16 months following placement of bilateral 370 cc, style 410 MX breast implants and 85 cc of large volume fat grafting to the right breast, and 145 cc to the left breast, she has an excellent cosmetic outcome (*right*).

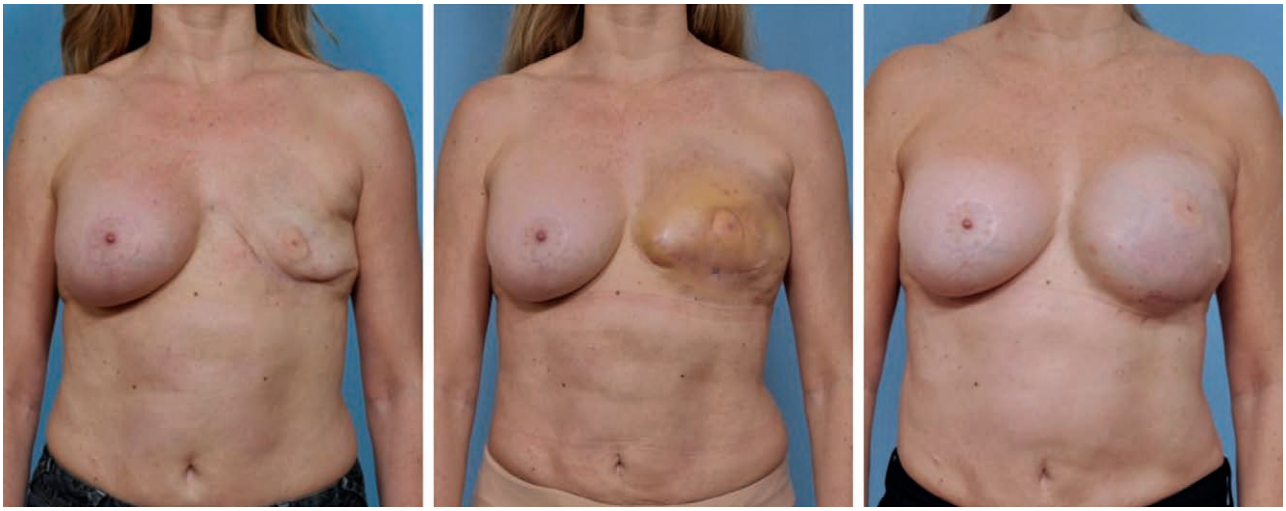

Fig. 4. Preoperative photographs of a failed left latissimus breast reconstruction (*left*), who underwent BRAVA preexpansion and 2 rounds of fat grafting of 725 cc (*center*), and 465 cc. She then underwent placement of a 600 cc style 45 permanent implant (6 month follow-up, lower right).

perform primary fat grafting of the pectoralis muscle and latissimus at the time of pedicled latissimus dorsi flap reconstruction to replace the need for tissue expanders and implants as traditionally performed with latissimus flap reconstruction.[33,34]

Simultaneous Implant Exchange with Fat

Prosthetic breast implants for cosmetic or reconstructive use can lead to complications such as pain, tissue thinning, asymmetry, malposition, and capsular contracture. Traditionally, these problems were addressed with implant exchange, capsulectomy, capsulotomy, a change in implant plane, placement of acellular dermal matrix, implant removal and autologous flap reconstruction, or implant removal alone. In 2012, Del Vecchio[35] introduced the concept of simultaneous implant exchange with fat (SIEF) as a new option for dealing with these complications. The technique as described in the original article by Del Vecchio utilizes the BRAVA system 2 weeks prior to surgery, although BRAVA is not today utilized in all cases. Fat is injected over the preexisting implant in the subcutaneous plane of the breast. The implant is then removed, lowering the interstitial pressure, allowing for further fat injection in the subcutaneous breast plane. It should be noted that capsulectomy or capsulectomies are avoided to maintain the separation of the original implant pocket. In this cardinal work, Del Vecchio shares his experience with 4 patients with preoperative breast and implant volumes ranging from 341 to 934 cc. Following SIEF, these patients obtained nearly identical breast volumes as measure on 3D scans. Based on his experience and previously published work, Del Vecchio recommends a 2:1 ratio of fat transplantation to desired classic implant size (Fig. 5).[26]

Abboud and Dibo[36] also performed large volume fat grafting immediately following implant removal. In this work, 160 breasts were prospectively studied. Fat was harvested with power-assisted liposuction and decanted but not centrifuged or rolled. Following removal of the breast implants, the fat was injected into the subcutaneous tissue using the power-assisted liposuction handle. The authors posit that sedimentation rather than centrifugation avoids compacting the fat, thus increasing the capacity of the recipient site and dispersing the fat and preventing it from coalescing. Additionally, power-assisted augmentation expands the recipient site via vibration and multilayer tunneling during fat injection. The mean injected volume was 420 cc per breast. With a cyst formation in 5.6% of breasts and a 2.5% infection rate, the large majority of surveyed patients indicated satisfaction with the results.

Management of Complications

With experience, fat necrosis and cyst formation becomes less common. However, both are known complications of fat grafting. We prefer to drain cysts in the office under local anesthesia. We have had good outcomes with this technique with low recurrence. Larger areas of fat necrosis can be removed with liposuction or needle band release. These areas can then be later regrafted to correct any defects.

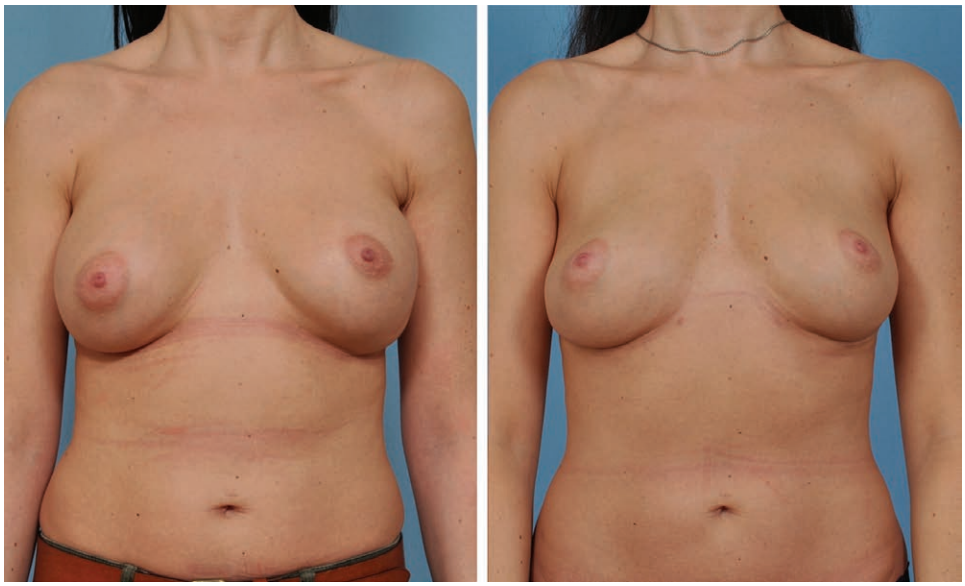

Fig. 5. Preopeartive (*left*) and 6 months status post SIEF with removal of bilateral 350 cc saline breast implants and placement of 340 cc and 345 cc of autologous fat to the right and left breasts, respectively (*right*).

Noncancer Reconstruction

The correction of tuberous breast deformities has traditionally required the use of breast implants or expanders. Recently, several authors published excellent, long-term reconstructive results with the use of autologous fat transfer.[15,19,37] Del Vecchio and Bucky[26] saw an average volume increase of 106% in these patients with the use of the BRAVA system pre- and postgrafting and reported excellent results when combined with ancillary procedures such as nipple-areola reductions and percutaneous inframammary fold release. Similarly, lipo-augmentation also has the potential to radically change the management of Poland syndrome that has traditionally required latissimus flaps and implants or tissue expanders for reconstruction.[38,39] A number of studies have shown excellent results using lipo-augmentation alone to reconstruct Poland syndrome patients.[15,19,39,40] The treatment of pectus excavatum, which has historically required more invasive procedures such as custom-designed silicone implants placement or the Nuss et al.[41] or Ravitch procedures[42] has also evolved due to fat grafting.[43]

SAFETY AND MONITORING

Cancer Monitoring and Detection

Structural changes to the breast occur with all breast surgery and are detectable on standard imaging.[44–50] Research has been performed to characterize the mammographic changes after lipoaugmentation of the breast.[51–53] Additionally, numerous long-term studies have evaluated and found fat grafting to the breast to be safe in the long term.[29,54,55]

In 2009, Illouz and Sterodimas[56] published a 25-year retrospective review of his experience with fat-grafting in over 800 patients with preoperative mammograms. Patients were divided into 3 groups: those with asymmetry after mastectomy and reconstruction, those with congenital breast asymmetry, and those requesting breast augmentation. Over 600 of these patients underwent mammography at 6 months and 1 year. Two hundred thirty of these patients had long-term (mean, 11.3 years) follow-up with yearly mammography showing mammography consistent with breast reduction surgery.[56] In 2012, Rubin et al.[57] compared the changes after breast reduction with those after fat grafting. Academic radiologists were blinded and given mammograms after either breast reduction or fat transfer. Scarring and masses requiring biopsy were found to be significantly more common after breast reduction compared with fat transfer. BiRAD scores were also found to be higher after breast reduction.[57]

In combination, these studies suggest that fat grafting, when performed appropriately, does not obscure or alter breast imagining. Based on this body of research, the American Society of Plastic Surgeons has changed its official stance, stating, "fat grafting may be considered for breast augmentation and correction of defects associated with medical conditions and previous breast surgeries."[16]

Cancer Recurrence

One of the main concerns associated with fat grafting to the breast has been increased risk for breast cancer, as well as increased cancer recurrence. Several well-designed studies have allayed these worries. Krastev et al.[58] performed a systematic review of the literature that found no differences in local regional recurrence rates in patients receiving autologous fat grafting following mastectomy or breast-conserving therapy when compared with control groups. In 2015, Gale et al.[59] performed a case-controlled study with 328 patients who received fat grafting following treatment for breast cancer. They found no difference in local, regional, or distant recurrence rates when compared with controls with a mean follow-up of 88 months following cancer resection and 32 months following fat grafting. This was the case in both postmastectomy patients undergoing fat grafting and patients undergoing fat grafting for correction of defects following breast-conserving therapy.[59]

Khouri et al.[29], reporting on their 7-year, multicenter experience with 488 patients undergoing breast reconstruction with Brava-assisted fat grafting, found a locoregional recurrence rate of 0.5% with an average follow-up time of 2.5 years. Numerous other reviews confirm similar low rates of locoregional recurrence following fat grafting for breast reconstruction.[54,60–62] In summary, current research suggests fat grafting for breast cancer reconstruction confers no addition risk for cancer recurrence.

CONCLUSIONS

Arguably, no plastic surgery technique has seen more evolution over the past 30 years as fat grafting. Lipoaugmentation has now become an essential tool for the reconstructive and aesthetic surgeon. The indications for small volume fat grafting to the breast have grown and evolved. Large volume fat grafting to the breast is becoming more common place and is remarkable for revision reconstruction and improving the aesthetic results of our reconstructive patients. Despite demonstrated safety, any surgeon employing these techniques should be well-versed in cancer monitoring and recurrence following fat grafting to the breast. This article has summarized the research in fat grafting for breast reconstruction to allow the reader to be more comfortable when offering and utilizing the full potential of this technique for the benefit of his or her patients.

Louis P. Bucky, MD
Pennsylvania Hospital
230 W. Washington Square, #101
Philadelphia, PA 19106

REFERENCES

1. Neuber F. Fettransplantation. *Chir Kongr Verhandl Deutsche Gesellsch Chir.* 1893;22:66–68.
2. Czerny V. Plastischer Ersatz der Brustdruse durch ein Lipom. *Zentralbl Chir.* 1895:72–75.
3. Illouz YG. Body contouring by lipolysis: a 5-year experience with over 3000 cases. *Plast Reconstr Surg.* 1983;72:591–597.
4. Chajchir A, Benzaquen I. Fat-grafting injection for soft-tissue augmentation. *Plast Reconstr Surg.* 1989;84:921–934; discussion 935.
5. Bircoll M. Autologous fat transplantation. *Plast Reconstr Surg.* 1987;79:492–493.
6. Bircoll M, Novack BH. Autologous fat transplantation employing liposuction techniques. *Ann Plast Surg.* 1987;18:327–329.
7. Bircoll M. Cosmetic breast augmentation utilizing autologous fat and liposuction techniques. *Plast Reconstr Surg.* 1987;79:267–271.
8. Report on autologous fat transplantation. ASPRS Ad-Hoc Committee on New Procedures, September 30, 1987. *Plast Surg Nurs.* 1987;7:140–141.
9. Coleman SR. Long-term survival of fat transplants: controlled demonstrations. *Aesthetic Plast Surg.* 1995;19:421–425.
10. Coleman SR. Facial recontouring with lipostructure. *Clin Plast Surg.* 1997;24:347–367.
11. Coleman SR. Structural fat grafting. *Aesthet Surg J.* 1998;18:386–388.
12. Delay E, Delaporte T, Sinna R. [Breast implant alternatives]. *Ann Chir Plast Esthet.* 2005;50:652–672.
13. Delay E, Delpierre J, Sinna R, et al. [How to improve breast implant reconstructions?]. *Ann Chir Plast Esthet.* 2005;50:582–594.
14. Rigotti G, Marchi A, Galiè M, et al. Clinical treatment of radiotherapy tissue damage by lipoaspirate transplant: a healing process mediated by adipose-derived adult stem cells. *Plast Reconstr Surg.* 2007;119:1409–1422; discussion 1423.
15. Coleman SR, Saboeiro AP. Fat grafting to the breast revisited: safety and efficacy. *Plast Reconstr Surg.* 2007;119:775–785; discussion 786.
16. Gutowski KA; ASPS Fat Graft Task Force. Current applications and safety of autologous fat grafts: a report of the ASPS fat graft task force. *Plast Reconstr Surg.* 2009;124:272–280.
17. Spear SL, Wilson HB, Lockwood MD. Fat injection to correct contour deformities in the reconstructed breast. *Plast Reconstr Surg.* 2005;116:1300–1305.
18. Kanchwala SK, Glatt BS, Conant EF, et al. Autologous fat grafting to the reconstructed breast: the management of acquired contour deformities. *Plast Reconstr Surg.* 2009;124:409–418.
19. Delay E, Guerid S. The role of fat grafting in breast reconstruction. *Clin Plast Surg.* 2015;42:315–323, vii.
20. Auclair E, Blondeel P, Del Vecchio DA. Composite breast augmentation: soft-tissue planning using implants and fat. *Plast Reconstr Surg.* 2013;132:558–568.
21. Del Vecchio D, Rohrich RJ. A classification of clinical fat grafting: different problems, different solutions. *Plast Reconstr Surg.* 2012;130:511–522.
22. Kling RE, Mehrara BJ, Pusic AL, et al. Trends in autologous fat grafting to the breast: a national survey of the American Society of Plastic Surgeons. *Plast Reconstr Surg.* 2013;132:35–46.

23. Del Vecchio DA, Del Vecchio SJ. The graft-to-capacity ratio: volumetric planning in large-volume fat transplantation. *Plast Reconstr Surg.* 2014;133:561–569.
24. Khouri RK, Schlenz I, Murphy BJ, et al. Nonsurgical breast enlargement using an external soft-tissue expansion system. *Plast Reconstr Surg.* 2000;105:2500–2512; discussion 2513.
25. Smith CJ, Khouri RK, Baker TJ. Initial experience with the Brava nonsurgical system of breast enhancement. *Plast Reconstr Surg.* 2002;110:1593–1595; author reply 1595.
26. Del Vecchio DA, Bucky LP. Breast augmentation using pre-expansion and autologous fat transplantation: a clinical radiographic study. *Plast Reconstr Surg.* 2011;127:2441–2450.
27. Del Vecchio D. Breast reconstruction for breast asymmetry using recipient site pre-expansion and autologous fat grafting: a case report. *Ann Plast Surg.* 2009;62:523–527.
28. Khouri RK, Rigotti G, Cardoso E, et al. Megavolume autologous fat transfer: Part I. Theory and principles. *Plast Reconstr Surg.* 2014;133:550–557.
29. Khouri RK, Rigotti G, Khouri RK Jr, et al. Tissue-engineered breast reconstruction with Brava-assisted fat grafting: a 7-year, 488-patient, multicenter experience. *Plast Reconstr Surg.* 2015;135:643–658.
30. Uda H, Sugawara Y, Sarukawa S, Sunaga A. Brava and autologous fat grafting for breast reconstruction after cancer surgery. *Plast Reconstr Surg.* 2014;133:203–213.
31. Chang CS, Lanni MA, Lamelas AM, et al. Abstract: identifying risk factors for fat necrosis after autologous fat transplantation to the breast. *Plast Reconstr Surg.* 2016;4:135–136.
32. Laporta R, Longo B, Sorotos M, et al. Breast reconstruction with delayed fat-graft-augmented DIEP flap in patients with insufficient donor-site volume. *Aesthetic Plast Surg.* 2015;39:339–349.
33. Niddam J, Vidal L, Hersant B, et al. Primary fat grafting to the pectoralis muscle during latissimus dorsi breast reconstruction. *Plast Reconstr Surg Glob Open.* 2016;4:e1059.
34. Langstein HN. Total autologous latissimus dorsi breast reconstruction with immediate fat grafting. In: Eilat, Israel: Red Sea Symposium; 2015.
35. Del Vecchio DA. "SIEF"—simultaneous implant exchange with fat: a new option in revision breast implant surgery. *Plast Reconstr Surg.* 2012;130:1187–1196.
36. Abboud MH, Dibo SA. Immediate large-volume grafting of autologous fat to the breast following implant removal. *Aesthet Surg J.* 2015;35:819–829.
37. Delay E, Sinna R, Ho Quoc C. Tuberous breast correction by fat grafting. *Aesthet Surg J.* 2013;33:522–528.
38. Delay E, Sinna R, Chekaroua K, et al. Lipomodeling of Poland's syndrome: a new treatment of the thoracic deformity. *Aesthetic Plast Surg.* 2010;34:218–225.
39. La Marca S, Delay E, Toussoun G, et al. [Treatment of Poland syndrome thorax deformity with the lipomodeling technique: about ten cases]. *Ann Chir Plast Esthet.* 2013;58:60–68.
40. Khouri R, Del Vecchio D. Breast reconstruction and augmentation using pre-expansion and autologous fat transplantation. *Clin Plast Surg.* 2009;36:269–280, viii.
41. Nuss D, Kelly RE Jr, Croitoru DP, et al. A 10-year review of a minimally invasive technique for the correction of pectus excavatum. *J Pediatr Surg.* 1998;33:545–552.
42. Ravitch MM. The operative treatment of pectus excavatum. *Ann Surg.* 1949;129:429–444.
43. Ho Quoc C, Delaporte T, Meruta A, et al. Breast asymmetry and pectus excavatum improvement with fat grafting. *Aesthet Surg J.* 2013;33:822–829.
44. Brown FE, Sargent SK, Cohen SR, et al. Mammographic changes following reduction mammaplasty. *Plast Reconstr Surg.* 1987;80:691–698.
45. Isaacs G, Rozner L, Tudball C. Breast lumps after reduction mammaplasty. *Ann Plast Surg.* 1985;15:394–399.
46. Miller CL, Feig SA, Fox JW 4th. Mammographic changes after reduction mammoplasty. *AJR Am J Roentgenol.* 1987;149:35–38.
47. Sickles EA, Herzog KA. Mammography of the postsurgical breast. *AJR Am J Roentgenol.* 1981;136:585–588.
48. Redfern AB, Ryan JJ, Su TC. Calcification of the fibrous capsule about mammary implants. *Plast Reconstr Surg.* 1977;59:249–251.
49. Danikas D, Theodorou SJ, Kokkalis G, et al. Mammographic findings following reduction mammoplasty. *Aesthetic Plast Surg.* 2001;25:283–285.
50. Abboud M, Vadoud-Seyedi J, De Mey A, et al. Incidence of calcifications in the breast after surgical reduction and liposuction. *Plast Reconstr Surg.* 1995;96:620–626.
51. Castelló JR, Barros J, Vázquez R. Giant liponecrotic pseudocyst after breast augmentation by fat injection. *Plast Reconstr Surg.* 1999;103:291–293.
52. Hyakusoku H, Ogawa R, Ono S, et al. Complications after autologous fat injection to the breast. *Plast Reconstr Surg.* 2009;123:360–370; discussion 371.
53. Carvajal J, Patiño JH. Mammographic findings after breast augmentation with autologous fat injection. *Aesthet Surg J.* 2008;28:153–162.
54. Spear SL, Coles CN, Leung BK, et al. The safety, effectiveness, and efficiency of autologous fat grafting in breast surgery. *Plast Reconstr Surg Glob Open.* 2016;4:e827.
55. Khouri RK, Khouri RK Jr, Rigotti G, et al. Aesthetic applications of Brava-assisted megavolume fat grafting to the breasts: a 9-year, 476-patient, multicenter experience. *Plast Reconstr Surg.* 2014;133:796–807; discussion 808-799.
56. Illouz YG, Sterodimas A. Autologous fat transplantation to the breast: a personal technique with 25 years of experience. *Aesthetic Plast Surg.* 2009;33:706–715.
57. Rubin JP, Coon D, Zuley M, et al. Mammographic changes after fat transfer to the breast compared with changes after breast reduction: a blinded study. *Plast Reconstr Surg.* 2012;129:1029–1038.
58. Krastev TK, Jonasse Y, Kon M. Oncological safety of autologous lipoaspirate grafting in breast cancer patients: a systematic review. *Ann Surg Oncol.* 2013;20:111–119.
59. Gale KL, Rakha EA, Ball G, et al. A case-controlled study of the oncologic safety of fat grafting. *Plast Reconstr Surg.* 2015;135:1263–1275.
60. Claro F Jr, Figueiredo JC, Zampar AG, et al. Applicability and safety of autologous fat for reconstruction of the breast. *Br J Surg.* 2012;99:768–780.
61. Fraser JK, Hedrick MH, Cohen SR. Oncologic risks of autologous fat grafting to the breast. *Aesthet Surg J.* 2011;31:68–75.
62. Petit JY, Maisonneuve P, Rotmensz N, et al. Fat grafting after invasive breast cancer: a matched case-control study. *Plast Reconstr Surg.* 2017;139:1292–1296.